

# Index of Suspicion

## 4

## Two Children with Presumed Inguinal Hernias

Jennifer Adair Williams, MD,\* Gordon Bruce, MD,<sup>†</sup> Nishit Patel, MD,<sup>†</sup>  
Jo-Ann Nesiama, MD, MS<sup>†</sup>

*\*Department of Pediatrics, Children's Health, Dallas, TX*

*<sup>†</sup>Department of Pediatric Emergency Medicine, University of Texas Southwestern Medical Center, Dallas, TX*

### CASE PRESENTATIONS

We present 2 patients, A and B, with a similar condition.

Patient A is a 7-year-old girl with no medical history who is referred to the emergency department by her pediatrician due to concern for incarcerated inguinal hernia. She has a 3-day history of genital area redness, pain, swelling, and dysuria. She has had similar, although less severe, episodes of inguinal area swelling without redness twice in the past year, which resolved spontaneously. She denies fevers, vomiting, or dyspnea. Her vital signs are normal. She does not have any breast development or pubic hair, with a sexual maturity rating (SMR) of 1. Her physical examination reveals bilateral labial redness, tenderness with swelling extending to the suprapubic and bilateral inguinal area, and an enlarged clitoris with no vaginal opening (Fig 1). Findings from a complete blood cell count, comprehensive metabolic panel, and urinalysis are unremarkable. Pelvic ultrasonography shows cellulitis of the labia minora without discrete fluid collection or abscess, testicles in the bilateral inguinal canals, and no definite uterus or ovaries.

Patient B is an 11-year-old girl with no medical history who presents to the emergency department with a 4-day history of abdominal pain, fever, nausea, and vomiting concerning for appendicitis. Her vital signs are normal. Her examination reveals right lower quadrant abdominal tenderness. She has SMR 2 breasts, SMR 1 pubic hair, and normal external female genitalia. Her pediatric appendicitis score is intermediate, and ultrasonography of her appendix is inconclusive. A follow-up computed tomographic scan of her abdomen and pelvis shows appendicitis but also reveals an absent uterus and gonadal tissue in the right hemipelvis as well as a soft tissue mass in the left inguinal canal that appears more like a testicle than an ovary (Fig 2).

### DISCUSSION

#### The Condition

Androgen insensitivity syndrome (AIS), a disorder of sexual development, is a syndrome whereby a genotypically XY individual is phenotypically female due to a resistance to the androgen hormones through a mutation in the androgen receptor. There can be complete or partial resistance, as demonstrated in the

**AUTHOR DISCLOSURE** Drs Williams, Bruce, Patel, and Nesiama have disclosed no financial relationships relevant to this article. This commentary does not contain a discussion of an unapproved/investigative use of a commercial product/device.



Figure 1. Physical examination findings for patient A.

cases presented. During embryotic development, the production of anti-Müllerian hormone (AMH) inhibits formation of the Müllerian ducts. These structures ultimately form the uterus, cervix, and proximal vagina. In AIS, AMH is present, but androgens secreted from the Leydig cells are not recognized and, therefore, no Wolffian ducts form to produce male genitalia. Because the innate tendency

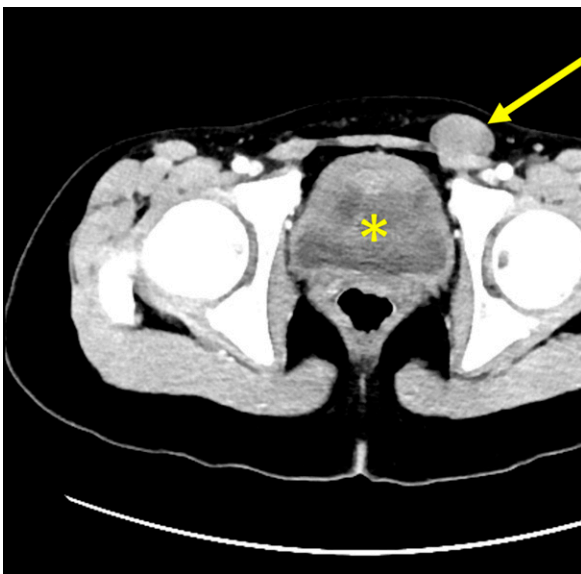


Figure 2. Computed tomographic scan of patient B with absent uterus (asterisk) and gonadal tissue in the left groin (arrow).

of human sexual development is female, the patient will develop external female genitalia. The syndrome may be first recognized with inguinal swelling in a phenotypic female, primary amenorrhea, or as a result of mismatch between prenatal sex prediction and the phenotype at birth. These patients go through puberty and develop estrogen through aromatization of the androgens. They enter puberty the same time as others and may be slightly taller, due to the growth-controlling region of the Y chromosome. There is a higher risk of gonadal tumors in AIS.

The pathogenesis of AIS is usually a missense mutation that encodes part of the androgen receptor. In complete AIS, the binding affinity is absent, whereas it is only altered in partial AIS. There are more than 800 mutations currently implicated in AIS. Whereas 30% of mutations are de novo, there is a X-linked inheritance pattern in complete AIS.

The differential diagnosis includes congenital adrenal hypoplasia, 5 $\alpha$ -reductase deficiency, and 3 $\beta$ -hydroxysteroid dehydrogenase type 3.

### Management

Management of AIS depends on the extent of the phenotype and should involve a multidisciplinary approach. Attention to various aspects, including functional, sexual, and psychological issues, should be undertaken. Furthermore, therapies such as gonadectomy, hormone replacement, and, in some cases, genitoplasty should also be discussed in accordance with the chosen sex and genetic advice.

### Patient Courses

Patient A was given clindamycin for 10 days and was referred to the endocrinologist and gynecologist for further evaluation.

After extensive evaluation, she was diagnosed as having partial AIS. Her pertinent laboratory values include elevated testosterone of 126 ng/dL (4.4 nmol/L) (reference range, <10 ng/dL [ $<0.35$  nmol/L]) and elevated AMH of 151 ng/mL (reference range, 0.53–7.78 ng/mL). The human chorionic gonadotropin stimulation test showed a normal testosterone to dihydrotestosterone ratio and a normal testosterone to androstenedione ratio. Fluorescence in situ hybridization and chromosomal microarray analysis showed 46, XY karyotype. No specific androgen receptor mutations were found on an androgen insensitivity panel. Of note, a physical examination revealing no vaginal opening in this patient during a previous visit to her pediatrician should have prompted earlier referral for evaluation.

She underwent a bilateral inguinal hernia repair, bilateral orchiectomy, and vaginoscopy with vaginal calibration. A pathology specimen showed no evidence of Leydig cell hyperplasia. She will undergo induction of puberty at approximately 10 years of age and be raised as a girl.

Patient B was given metronidazole and ceftriaxone for her appendicitis. During the laparoscopic appendectomy, a testiculoform right gonad was found, and she had a left gonad measuring 2×3 cm that was fixed in the inguinal canal. She also had bilateral inguinal hernia. No uterus was identified. A vaginal examination was performed under anesthesia and revealed a vagina measuring 5 to 6 cm with no palpable cervix.

She was diagnosed as having complete AIS. Her pertinent laboratory findings included karyotype 46, XY and an elevated testosterone level of 136 ng/dL (4.7 nmol/L). The family also plans for her gonads to be removed with estrogen therapy during puberty. This patient will not need vaginal dilation given the initial measurements of her vagina. She will also be raised as a girl.

#### Lessons for the Clinician

- Always complete a thorough external genital examination in any child with lower abdominal pain or inguinal area swelling.
- Androgen insensitivity syndrome (AIS) should be included in the differential diagnosis for a girl with inguinal area swelling or primary amenorrhea.
- Management of AIS should be undertaken by a multidisciplinary team.
- Gonadectomy is recommended because of the small risk of gonadal tumors.

*Suggested Readings for this article are at <http://pedsinreview.aappublications.org/content/40/9/491>.*

## Suggested Readings

Gil AT, Salgado M. Bilateral inguinal hernia in a female child. *BMJ Case Rep.* 2014;2014:bcr2013202452

Gîngu C, Dick A, Pătrăscoiu S, et al. Testicular feminization: complete androgen insensitivity syndrome: discussions based on a case report. *Rom J Morphol Embryol.* 2014;55(1):177-181

Hannema SE, Scott IS, Rajpert-De Meyts E, Skakkebaek NE, Coleman N, Hughes IA. Testicular development in the complete androgen insensitivity syndrome. *J Pathol.* 2006;208(4):518-527

Hughes IA, Davies JD, Bunch TI, Pasterski V, Mastroyannopoulou K, MacDougall J. Androgen insensitivity syndrome. *Lancet.* 2012;380(9851):1419-1428

Oakes MB, Eyvazzadeh AD, Quint E, Smith YR. Complete androgen insensitivity syndrome: a review. *J Pediatr Adolesc Gynecol.* 2008;21(6):305-310

**Case 4: Two Children with Presumed Inguinal Hernias**  
Jennifer Adair Williams, Gordon Bruce, Nishit Patel and Jo-Ann Nesiama  
*Pediatrics in Review* 2019;40;491  
DOI: 10.1542/pir.2017-0138

**Updated Information & Services**

including high resolution figures, can be found at:  
<http://pedsinreview.aappublications.org/content/40/9/491>

**References**

This article cites 4 articles, 0 of which you can access for free at:  
<http://pedsinreview.aappublications.org/content/40/9/491.full#ref-list-1>

**Subspecialty Collections**

This article, along with others on similar topics, appears in the following collection(s):  
**Gynecology**  
[http://classic.pedsinreview.aappublications.org/cgi/collection/gynecology\\_sub](http://classic.pedsinreview.aappublications.org/cgi/collection/gynecology_sub)  
**Urology**  
[http://classic.pedsinreview.aappublications.org/cgi/collection/urology\\_sub](http://classic.pedsinreview.aappublications.org/cgi/collection/urology_sub)  
**Genitourinary Disorders**  
[http://classic.pedsinreview.aappublications.org/cgi/collection/genitourinary\\_disorders\\_sub](http://classic.pedsinreview.aappublications.org/cgi/collection/genitourinary_disorders_sub)

**Permissions & Licensing**

Information about reproducing this article in parts (figures, tables) or in its entirety can be found online at:  
<https://shop.aap.org/licensing-permissions/>

**Reprints**

Information about ordering reprints can be found online:  
<http://classic.pedsinreview.aappublications.org/content/reprints>



## Case 4: Two Children with Presumed Inguinal Hernias

Jennifer Adair Williams, Gordon Bruce, Nishit Patel and Jo-Ann Nesiama

*Pediatrics in Review* 2019;40;491

DOI: 10.1542/pir.2017-0138

The online version of this article, along with updated information and services, is located on the World Wide Web at:

<http://pedsinreview.aappublications.org/content/40/9/491>

Pediatrics in Review is the official journal of the American Academy of Pediatrics. A monthly publication, it has been published continuously since 1979. Pediatrics in Review is owned, published, and trademarked by the American Academy of Pediatrics, 345 Park Avenue, Itasca, Illinois, 60143. Copyright © 2019 by the American Academy of Pediatrics. All rights reserved. Print ISSN: 0191-9601.

# American Academy of Pediatrics

DEDICATED TO THE HEALTH OF ALL CHILDREN®

