

Eyes, ears, mouth and nose

Tips regarding eye examination

Work from outside in

Special tests:

- Red Reflex
- Visual acuity Charts - LogMar, Allen chart (?too culturally specific), HOTV, Tumbling E
- Strabismus - cover/uncover testing (starting around 3-4 months)

Read CPS Statement: Vision screening in infants, children and youth

Preventing ophthalmia neonatorum

Visual Acuity

Normal development of vision:

Newborn – 20/800-20/200 (everything is blurry), can focus 8-10 inches from face

2 months – 20/150 - more fixing on faces

3-4 months – 20/60 - Eyes moving together (not crossed)

5 months – Good colour vision

Most children are natural hyperopic (Farsighted) to begin with

Visual acuity

Myopia – near sightedness

Hyperopia – far sightedness

Astigmatism – Asymmetric curvature of the eye

Anisometropia – Two eyes have different refractive errors

Strabismus

Amblyopia – Decreased vision in one or both eyes due to abnormal vision development. Impaired neuronal connection between eye and brain. Leading cause of vision loss amongst children

- Due to *refractive error, strabismus, deprivational*

- Ways to deal – glasses, patching, drops (ie atropine)

- Needs to treat by 8 years of age (before vision is set). NIH has studies with teenagers being treated up to age 14, but generally earlier, the better

Strabismus

Esotropia – Eye deviated inward

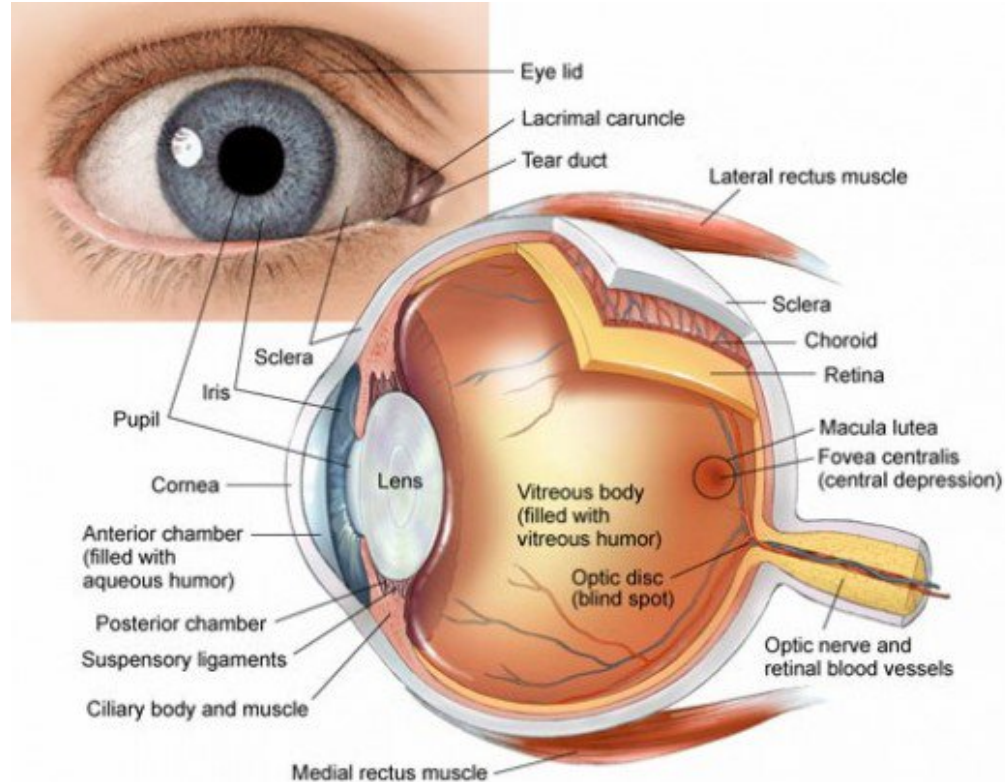
Exotropia – Eye deviated outward

Hypotropia – Eye deviated downward

Hypertropia – Eye deviated upward

Tropia vs phoria - **tropia** is a misalignment of the two eyes when a patient is looking with both eyes uncovered (always present) A **phoria** (or latent deviation) only appears when binocular viewing is broken and the two eyes are no longer looking at the same object

Starting from the outside in...



Lids, lacrimal glands, lashes

- Hordeolum, chalazion, blepharitis

- Blepharitis – inflammation of the eyelid – bacteria and oily flakes at the base of the eyelashes
- Hordeolum – Inflamed cyst at the margin of the eyelid (blocked gland) - acute focal infectious process
- Chalazion – Cystic mass caused by blockage of meibonium gland (which helps produce oil) - chronic, non-infectious granulomatous reaction, typically painless

- Nasolacrimal duct obstruction

- Common cause of tearing in newborns
- Typically resolves by age 1 – 1.5 - refer to ophtho for probing if not improved
- Complications include dacrocystitis, constant purulent discharge of eye
- Rule out congenital glaucoma

Lids, lacrimal glands, lashes

- Ptosis

- Congenital – most common is due to poor development of levator palpebrae superioris muscle

- Acquired – Myasthenia gravis, Horner's syndrome, 3rd nerve palsy, eyelid mass (ie hemangioma)

- Consider referral to ophtho if the lid droop is obscuring the visual field (Can cause deprivational amblyopia)

Conjunctiva

- Connective tissue attached to the eyeball (bulbar conjunctiva) and then reflected in the palpebral fissure (palpebral conjunctiva)
 - Bilateral disease- usually implies allergic or infectious
 - Unilateral – chemical, toxic, mechanical (ie foreign body)
- **Allergic conjunctivitis** - subacute onset, ++pruritis, clear/watery discharge, chemosis is common (swelling/edema of the conjunctiva)
- **Viral conjunctivitis** - acute to subacute onset, no to clear discharge, may have preauricular adenopathy, no treatment necessary
- **Bacterial conjunctivitis** - acute onset, ++purulent discharge, moderate erythema,
- Can be involved in mucocutaneous disease (SJS, TEN, etc)

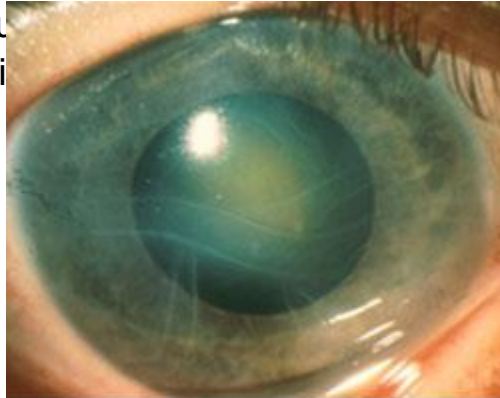
Sclera

- White part of the eye underneath the conjunctiva
- Disease processes:
 - Jaundice - Scleral icterus
 - Osteogenesis imperfecta - thinner sclera leads to the appearance of blueness of the sclera

Cornea

- Glaucoma

- Increased ocular pressure causing damage to optic nerve
- Most cases have no identifiable cause
- Secondary - aniridia, Sturge-Weber Syndrome, neurofibromatosis, chronic steroid use, trauma, or previous eye surgery
- s/sx – excessive tearing, li... anterior part of eye (iris appears dull)



Anterior chamber

- Uveitis
 - Inflammation the anterior chamber of the eye
 - Typically seen in JIA – can be asymptomatic but can lead to cataracts, vision loss etc
 - Needs to be screened for
 - Asymptomatic typically in oligoarticular, RF negative polyarticular JIA
 - Acute (symptomatic) uveitis can present in enthesitis-related JIA

Iris

- Anisocoria

- Difference in pupil size (seen normally in 20% of population, typically <1mm difference)
- Check in low light and bright light situations - If the difference in size between the pupils increases in the dark, then the smaller (miotic) pupil may not be dilating well and could be the abnormal one. Conversely, if the difference in pupil size increases in bright lighting, then the larger (mydriatic) pupil may be the abnormal one because it is not constricting normally

- Problems with dilation

- Inflammation, Horner's syndrome (ptosis, miosis and anhidrosis)
- Congenital – due to brachial plexus injury
- Acquired – problems in head and neck (tumour, inflammation, trauma). Consider neuroblastoma

Iris

Heterochromia

- Different colours of the iris
- Most cases, children experience no other symptoms
- Can be associated with: Horner's syndrome, Sturge-Weber, Waardenburg, Hirschsprung, etc
- If noted, should be assessed by ophtho to ensure to underlying disease



Iris

Aniridia

- Absence of the iris, usually bilateral
- Transmitted as autosomal dominant or may be sporadic
- Think about screening for Wilms tumour

Coloboma

- Incomplete fusion of the embryonic optic cup
- Can involve iris all the way back to the optic nerve
- Associated with CHARGE (coloboma, heart, atresia choanae, growth

Lens

Cataracts

If obscuring visual field, need to be removed!

Congenital - Unilateral usually isolated sporadic incidents, may be associated with trauma, intrauterine infections (ie rubella)

Bilateral - Typically inherited and associated with disease

- Trisomy 13/18/21
- Myotonic dystrophy
- TORCH

Acquired

- trauma – can occur months to years after initial injury
- Secondary to medications (ie prolonged steroid (glucocorticoid use)

Lens

Displacement

Can be related to trauma, tumour

Hereditary causes are rare

- Marfans - dislocation is superior and temporal
- Homocystinuria - dislocation is medial and inferior

Retina/optic nerve

ROP - Read the CPS statement

Retinoblastoma

Papilledema

Retinoblastoma

Inherited in AD pattern

Most common childhood tumour – typically presents by age 12-15 months
(bilateral) 18- 24 months (unilateral)

Papilledema

Bilateral optic disc swelling secondary to elevated intraocular pressure

(Subarachnoid space is continuous with the optic sheath, so as CSF pressure increases, gets transmitted towards the optic disc)

Typically no effect on visual acuity until advanced disease present

Causes: Anything that causes increased intracranial pressure (fluid, tumour, inflammation), IIH, medications (corticosteroids, lithium, Accutane, tetracycline)

ENT

CPS statements

- Acute management of croup in the Emergency Department
- Ankyloglossia and breastfeeding
- Management of acute otitis media in children 6 months or older
- Acute otitis externa

Congenital Deformities of the ear

Microtia/anotia – small or missing external +/- medial ear (aural atresia)

- Typically associated with craniofacial abn on the same side
- Hearing screen and renal US should be done
- May be associated with congenital rubella, maternal medication use (Isotretinoin) or syndromes such as Treacher-Collins

Large ears – more than 2cm from the head - otoplasty

Ear tags/ Ear pits – do not need to do renal ultrasound routinely unless other concerns

Typically genetic, ask to see parents' or siblings' ears

Sinuses

Table 1. The Development Of The Sinuses

Sinus	Gestational Month When Development Starts	Present in Clinically Significant Size	Fully Developed
Maxillary	2	Birth	12 years
Ethmoid	3	Birth	12 years
Frontal	4	3 years	18-20 years
Sphenoid	3	8 years	12-15 years

Sinusitis risk factors – craniofacial abn, trauma, GERD, URI, allergies, dental infections, nasal foreign objects

Same bugs as AOM

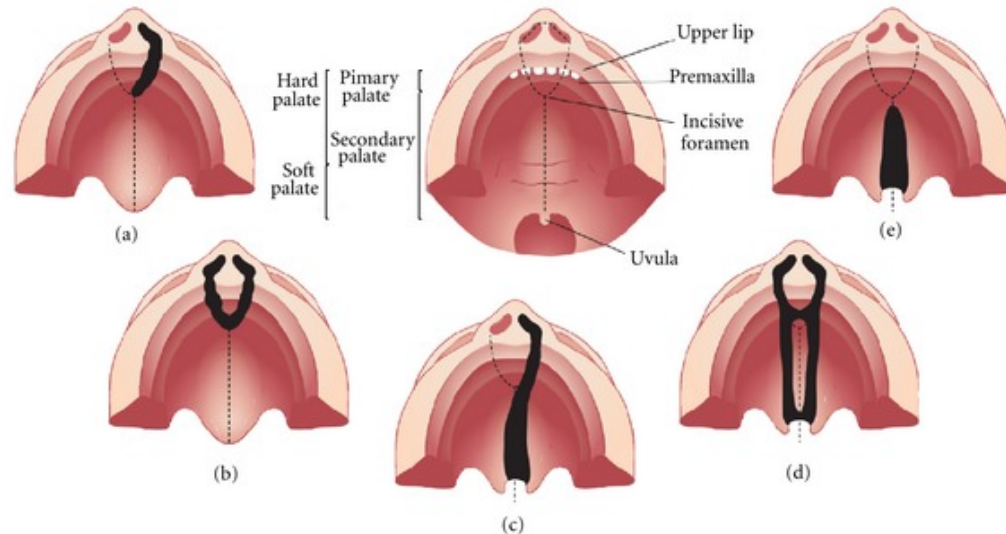
Stridor/noisy breathing

Work your way anatomically

- Choanal atresia
- Hypertrophic adenoids/tonsils
- Retropharyngeal abscess
- Epiglottitis
- vocal cord dysfunction - ?prev PDA ligation, prolonged intubation
- Laryngomalacia - most common cause of chronic stridor
- Croup - most common cause of acute stridor
- subglottic stenosis - traumatic intubation
- subglottic hemangioma - ?any hemangioma in beard distribution
- Foreign body
- Trachea - tracheomalacia

Cleft lip/palate

- Can occur as CL, CP or CL/P
- CL is seen laterally and can affect the upper lip only or deeper into the maxilla and primary palate



Cleft lip/palate

Increased risk for feeding difficulties, AOM (typically get prophylactic ear tubes), speech and language delays/difficulties, dental abn, psychological difficulties

Cleft lip repaired first (around 3 months, with T-tubes placed) with palate repair around 1 year

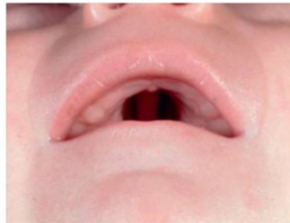Need ongoing surgeries for dental abnormalities

Cleft Palate

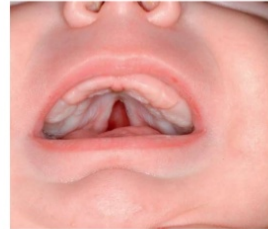Isolated cleft palate has different embryonic origins compared to CL/P

May be U-shaped or V-shaped

Pierre Robin Sequence - Micrognathia, cleft palate, glossoptosis/airway obstruction



Classic u shaped
cleft palate

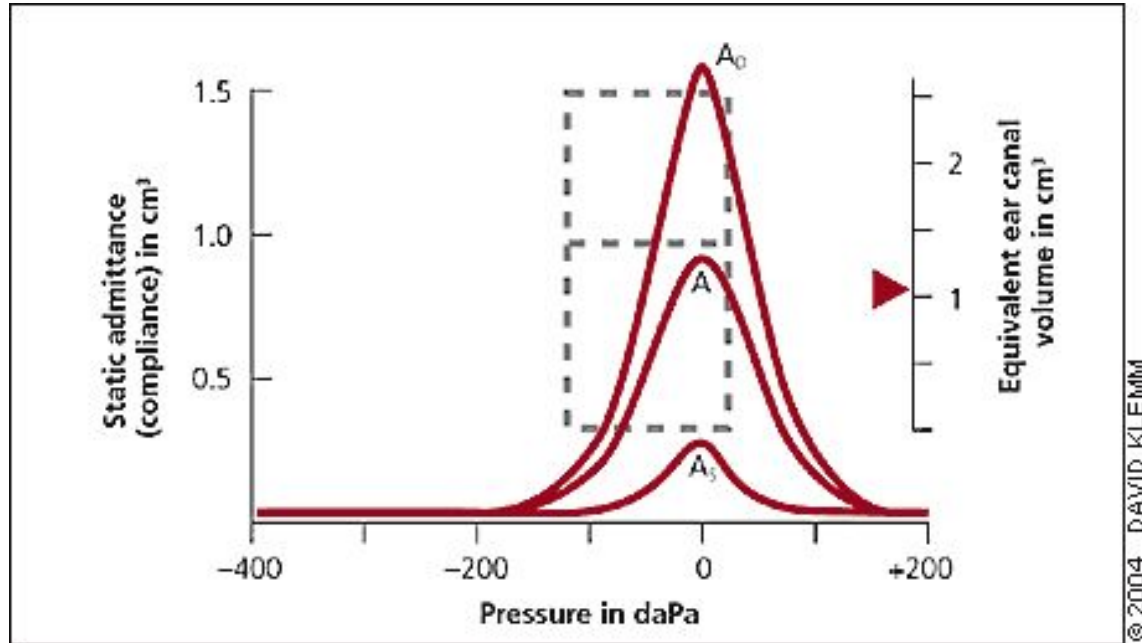


V shaped cleft
palate

Tympanograms

- Provides information regarding fluid in the middle ear, movement of the middle ear and volume of inner ear
- Sound + microphone, vacuum pump
- Not valid in infants <7 months (everything is too floppy and you get false results)
- Can be useful in OM with effusion and to some extent acute otitis

Interpreting Tympanogram



Normal tymp - normal pressure and ear canal volume

Abn tymp

A - poor mvmt likely secondary to Effusion, tumour, cholesteotoma etc

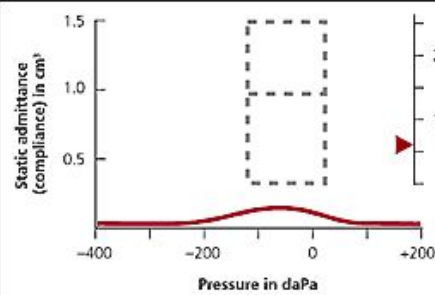
B - misplaced probe or earwax

C - High volume = t-tube, perf

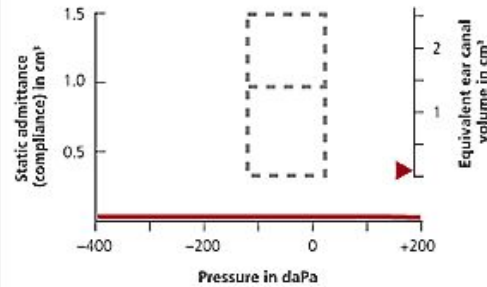
D - May be resolving/starting effusion

E - Negative pressure (eustachian tube dysfunction, viral URTI)

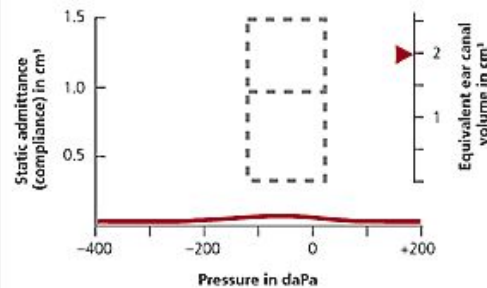
F - High pressure, likely bulging TM associated with AOM



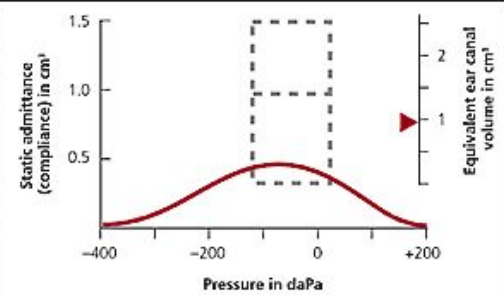
A. Type B tympanogram, normal ear canal volume.



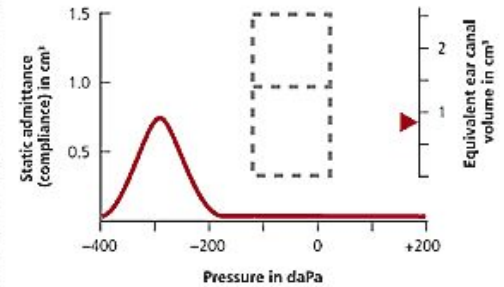
B. Type B tympanogram, low ear canal volume.



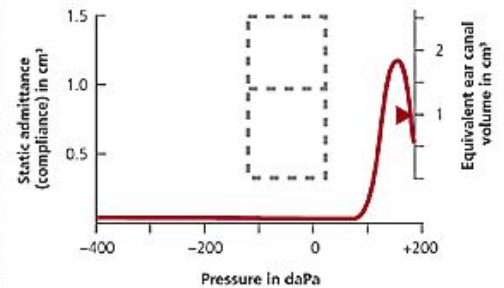
C. Type B tympanogram, high ear canal volume.



D. Tympanogram with wide curve.



E. Type C tympanogram with significantly negative peak pressure.



F. Tympanogram with a high peak pressure.

Derm

Important CPS statements to know

- Tanning

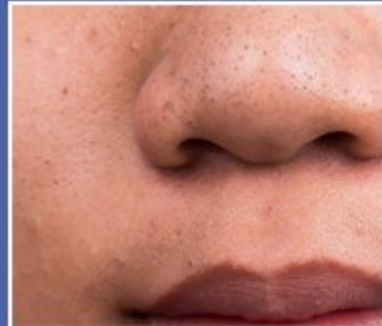Acne

Affects face, can affect back and chest

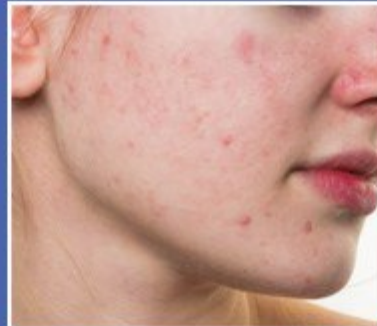Mild – open or closed comedones – (white heads/black heads)

Moderate – Inflamed skin forming papules or pustules

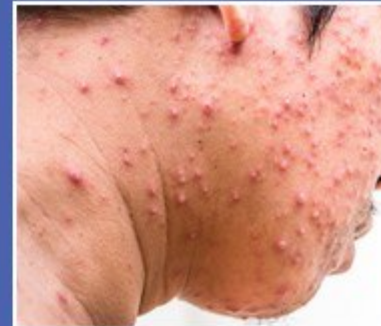Severe – Papular/pustular and can have nodules. Typically leads to scarring



MILD



MODERATE



SEVERE

Acne treatment

Regulated by androgen production

All patients should be encouraged to cleanse (Cetaphil, Septro gel)

Topical astringents – salicylic acid, benzoxyl peroxide

Topical retinoids - Adapalene

Oral agents – Antibiotics (Minocycline, tetracycline, clindamycin), spironolactone (selective aldosterone antagonist), OCP (females) and Epuris (formally Accutane) in severe scarring

Acne variants

Neonatal acne – first few weeks to months of life

Typically resolves on its own

Tuberous sclerosis – facial angiofibromas can be mistaken for acne

Appear after 4 years of age

Vesiculobullous disease

Fluid filled lesions

Vesicles <0.5cm, bullae >0.5cm

DDx:

Infectious - HSV, VZV, SSSS

Genodermatoses - Epidermolysis bullosa, incontinentia pigmenti

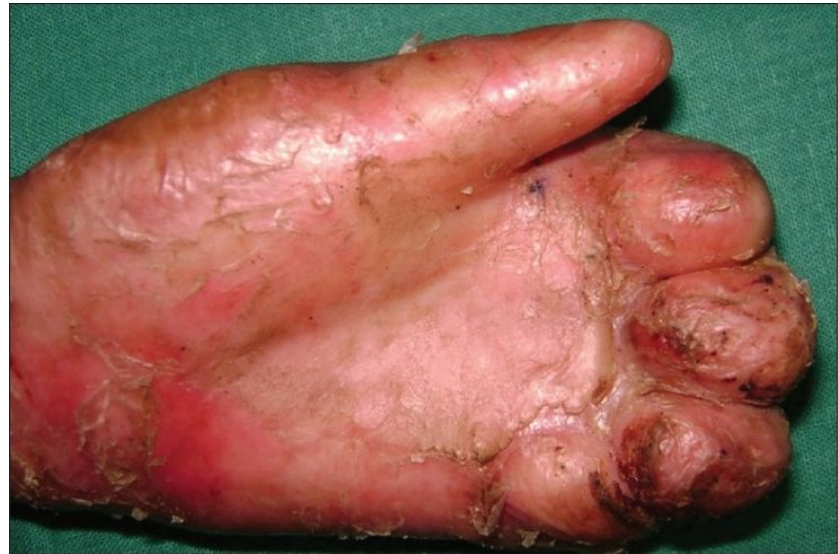Drug Reaction - SJS, TEN

Trauma - Bites, stings, burns

Autoimmune - Pemphigus

Epidermolysis bullosa

Connective tissue disorder cause blistering of skin with very minor trauma – complications include pain, infection, squamous cell carcinoma, mitten-hand deformity



Incontinentia Pigmenti

- X-linked dominant (male fetuses tend not to survive)
- Skin changes evolve over time – blistering rash at birth/infancy --> heals and forms wart-like skin growths --> hyperpigmentation that forms swirl patterns --> hypopigmentation
- Can affect eyes, nails, hair development
- May have developmental delay, seizures

