SCOLIOSIS

Defined as coronal plane curvature of > 10 degrees by Cob method

Idiopathic

- infantile (0-3yr)
- juvenile (3-10 yr)
- adolescent (> 10 yr, 70%)

Refer if:
- premenarchal and angle > 20 degrees
- postmenarchal and angle > 30 degrees
- progression of more than 5 degrees
- all infantile/juvenile

Congenital

Failure of formation
- wedge vertebrae
- hemivertebrae

Failure of segmentation
- unilateral bar
- block vertebrae
- mixed

Neuromuscular

UMN
- CP
- Friedrich ataxia
- CMT
- syringomyelia
- spinal cord tumour
- spinal cord trauma

LMN
- polio
- spinal muscular atrophy

Myopathy

- Duchenne
- Arhtrogryposis
- Other

Syndromes

- NF
- Marfan

Compensatory
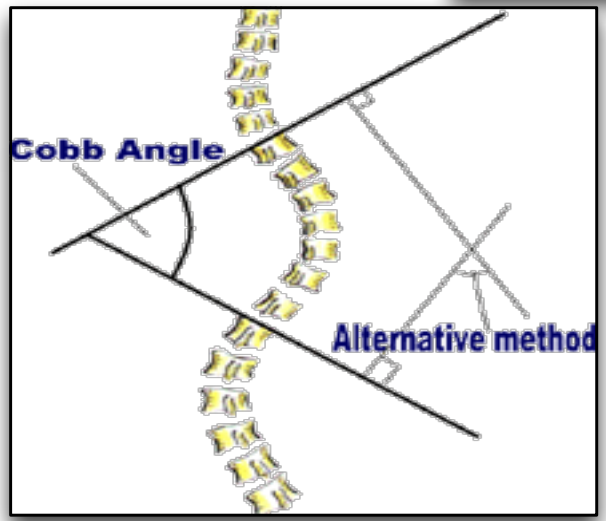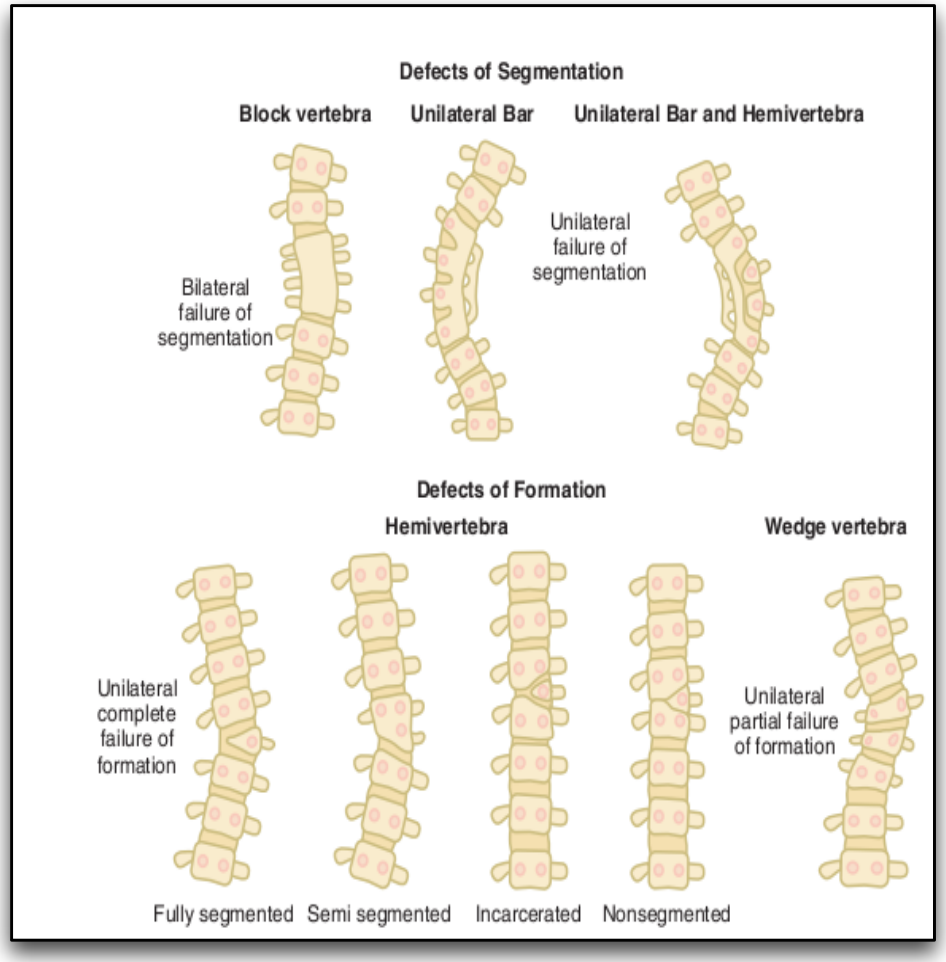
- Leg length discrepancy